

Accuracy of working length determination using cone beam computed tomography, periapical radiography, and apex locator: In vivo study

Awat Subhi Mahmood^{1*}, Bestoon Muhammad Faraj²

¹ BDS candidate of KHCMS of restorative dentistry, Ministry of Health, Shorsh Dental Training Center, Sulaymaniyah, Iraq.

² BDS, HDD, MSC, PhD, Prof, Ministry of Higher Education, University of Sulaymaniyah, Iraq.

*Email: awat86awat@yahoo.com

Received: 17 August 2023 / Revised: 19 September 2023 / Accepted: 29 September 2023/ Published online: 25 November 2023.

How to cite: Mahmood, A.S., Muhammad Faraj, B. (2023). Accuracy of working length determination using cone beam computed tomography, periapical radiography, and apex locator: In vivo study, *Journal of Wildlife and Biodiversity*, 7 (Special Issue), 1-12. DOI: <https://doi.org/10.5281/zenodo.10206781>

Abstract

Cone-beam computed Tomography has emerged as a promising tool for achieving a more precise determination of working length in endodontic treatment. The study aimed to evaluate the accuracy of determining working length using Cone-Beam Computed Tomography, periapical radiography, and an apex finder in endodontic treatment. This study was conducted as a Descriptive analytical study at the Shorsh Teaching Dental Center in Sulaimani City, Iraq, between 2022-2023. A random selection method was employed to pick a total of 50 patients. First, it was taken using a parallel periapical X-ray, then the length was measured on that X-ray, and finally, the length was measured with an apex finder (cox C_ROOT I). The three metrics were gathered, and compared, and the outcomes were subsequently scrutinized through Pearson tests and a two-way analysis of variance. A significance threshold of 0.05 was established. The results showed significant differences among the methods, with high correlations between Cone-Beam Computed Tomography and Standard reading ($R^2=0.996$, p -value < 0.0001), Periapical X-ray and Standard reading ($R^2=0.969$, p -value < 0.0001), and Apex locator and Standard reading ($R^2=0.989$, p -value < 0.0001). Cone-Beam Computed Tomography also demonstrated a strong correlation with Periapical X-ray ($R^2=0.971$, p -value < 0.0001) and Apex locator ($R^2=0.995$, p -value < 0.0001). Cone-beam computed Tomography is a more accurate method for determining the working length than periapical radiography and apex finder.

Keywords: Cone-Beam Computed Tomography, Dental Radiography, Electronic Apex Locator, Tooth Apex

Introduction

The phrase "radiographic working length" is used in dentistry to measure the space between the tip of a tooth's root and the location where the root canal treatment should stop (Sharma Col & Arora Maj Gen V., 2010). The complexity of the apical third of the root canals' structural makeup may make endodontic therapy difficult for teeth with apical periodontitis. sequence of surgical operations, including coronal access, root canal preparation, and filling influences the removal of bacteria inside the root canal system (de Morais et al., 2016).

In addition, technological advancements have improved endodontic treatment, making it more precise, reasonable, and less stressful for pros (Kim et al., 2008; Vieyra et al., 2010; Yildirim et al., 2017). However, these two approaches have drawbacks and restrictions. New imaging methods, including digital radiography, densitometry, computed tomography, magnetic resonance imaging, ultrasound, and radioactive procedures, have been incorporated into clinical practice (Sherwood et al., 2021). These finely detailed images offer a high-definition perspective of the oral components and facilitate the prompt detection of alterations in the maxillofacial formations (Sherrard et al., 2010). In opposition to periapical radiography, C.B.C.T. represents a substantial method that has only recently found utility in dentistry and holds substantial promise for practical clinical use. Its role in the treatment approach, disease diagnosis, patient management, and illness prognosis is noteworthy. C.B.C.T. scans can offer more precise W.L. measurements by leveraging existing data. However, the database search results show that there have been limited studies in this field in recent years, and most of the studies are old. Also, very limited studies have compared these methods simultaneously; Therefore, it was necessary to conduct a study to compare the accuracy of determining W.L. using C.B.C.T., conventional periapical radiographs, and an electronic apex finder in Iraq.

Martial and methods

This study was conducted as a Descriptive analytical study at the Shorsh Teaching Dental Center in Sulaimani City, Iraq, between 2022-2023. This initial clinical investigation examined 50 unextracted single-rooted teeth, including upper and lower anterior teeth, from 50 patients referred to Shorsh Teaching Dental Center in Sulaimani City.

All patients completed informed consent forms after being informed about the research. Exclusion criteria included teeth with severe, unusual changes such as twisted buccal roots or

three fused roots, extra coronal metal restorations, reluctance to continue, Calcified canals, and endodontically treated teeth.

With a focal tube of 0.8×0.8 mm and Kodak Insight E-films (Eastman Kodak Co, Rochester, NY, U.S.A.), the Spectro 70× x-ray system (Dabi Atlante, Ribeiro Preto, S.P., Brazil) was used to acquire all periapical radiographs. All images underwent automated processing.

The access holes were made with #1012 and 2200 diamond burs. (KG Sorensen, Agerskov, Denmark). After finding the root canals, they were thoroughly flushed with 5 mL of 2.5% hypochlorite sodium. Next, we used a size 15 stainless steel K-file to investigate the canals (Dentsply-Maillefer, Ballaigues, Switzerland). Then, with the help of the #2 and #3 Gates-Glidden drills and the #1 and #2 Largo burs, the coronal zones of the channels were prepared (Dentsply-Maillefer, Ballaigues, Switzerland).

After that, 1.0 mm of the silicon stopper's original distance was retracted, and this data were recorded.

An oral radiography expert took every measurement on the C.B.C.T. pictures using a specialized measurement instrument that was included with the C.B.C.T. scanner (Xoran 3.1.62; Xoran Technologies, Ann Arbor, MI, U.S.A.). (Figure 1)

Excel and analyzed using S.P.S.S. version 24 software. Pearson's correlation was used to evaluate inter-examiner reliability.

This study was approved by the Institutional Research Ethics Committee of Sulaimani University (approval number 1391 in 14\8\2022). All patients provided informed consent before participating in the study. The study was conducted in accordance with the Declaration of Helsinki and all applicable laws and regulations.

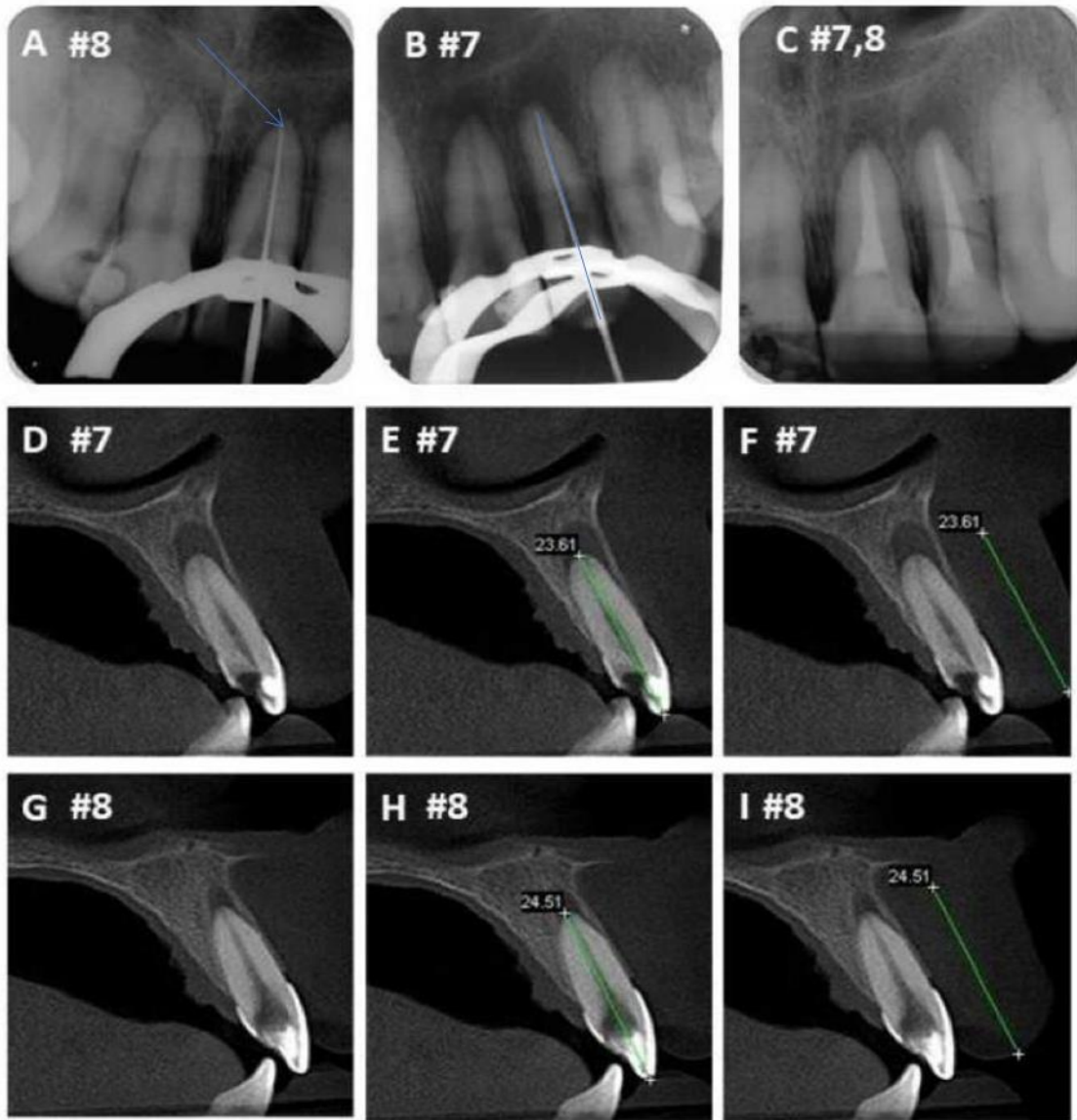


Figure (1). Determination of W.L. in upper and lower anterior teeth: A to C) periapical radiographs and D to I, the blue arrow in figure A refer to radiographic apical foramen while figure B refer to full W.L. from incisal edge to apical foramen) C.B.C.T. images.

Results

The cases studied in this research were 50 unextracted single-rooted teeth, including upper and lower anterior teeth. A Periapical X-ray was conducted for each root using a parallel technique for all teeth, and a C.B.C.T. image was taken to assess the W.L. before the root treatment.

The results showed that the mean, standard reading was $19.08 \pm (7.07)$ CI 95%; 17.08 – 20.23, and the mean C.B.C.T. $19.15 \pm (4.09)$ CI 95%; it was 20.32-17.99.

Also, the mean Periapical X-ray was $18.32 \pm (4.01)$ CI 95%; 17.18 – 19.46, and the mean Apex locator $18.7 \pm (4.11)$ CI 95%; 17.53-19.87 was obtained.

Based on this, the results showed a significant difference between Standard reading with C.B.C.T., Periapical X-ray, and Apex locator radiographs (p-value < 0.0001). In addition, the results showed a statistically significant difference between C.B.C.T. with Periapical X-ray and Apex locator (p-value < 0.0001). Also, there is a significant difference between the Periapical X-ray and Apex locator (p-value < 0.0001) Table (1).

Table 1. Mean ± SD Standard reading with 3-way radiography

Variable	No.	Mean ± SD	T- value	C-I	p-value
Standard reading	50	19.08 ± 4.07	33.149	17.92 ± 20.23	<0.0001
C.B.C.T.	50	19.15 ± 4.09	33.087	17.99 ± 20.32	<0.0001
Periapical X-ray	50	18.32 ± 4.01	32.31	17.18 ± 19.46	<0.0001
Apex locator	50	18.7 ± 4.11	32.11	17.53 ± 19.87	<0.0001
One-Sample T Test					

In this study, the correlation between standard reading and three radiography methods has been investigated. (p-value < 0.0001). The correlation between Standard reading and Periapical X-Ray is also a strong, direct, and significant correlation, which means that by increasing the Accuracy of Standard reading, the Accuracy of Periapical X-ray will also increase (p-value < 0.0001). Also, the correlation between the Standard reading and the Apex locator is a strong, direct, and significant correlation, which means that with the increase in the accuracy of the Standard reading, the accuracy of the Apex locator will also increase (p-value < 0.0001) Table (2)

Table 2. Correlation in Standard reading with 3-way radiography

Correlations		Standard reading	C.B.C.T	Periapical X-ray	Apex locator
Standard reading	Pearson Correlation	1	0.998**	0.984**	0.995**
	Sig. (2-tailed)		<0.0001	<0.0001	<0.0001
	N	50	50	50	50
C.B.C.T.	Pearson Correlation	0.998**	1	0.985**	0.997**
	Sig. (2-tailed)	<0.0001		<0.0001	<0.0001
	N	50	50	50	50
Periapical X-ray	Pearson Correlation	0.984**	0.985**	1	0.986**
	Sig. (2-tailed)	<0.0001	<0.0001		<0.0001
	N	50	50	50	50
Apex locator	Pearson Correlation	0.995**	0.997**	0.986**	1
	Sig. (2-tailed)	<0.0001	<0.0001	<0.0001	
	N	50	50	50	50
**. Correlation is significant at the 0.01 level (2-tailed).					

The distribution charts show strong and highly significant correlations between C.B.C.T. and Standard reading ($R^2=0.996$, $p\text{-value} < 0.0001$, Figure (2)) as well as between Periapical X-ray and Standard reading ($R^2=0.969$, $p\text{-value} < 0.0001$, Figure (3)).

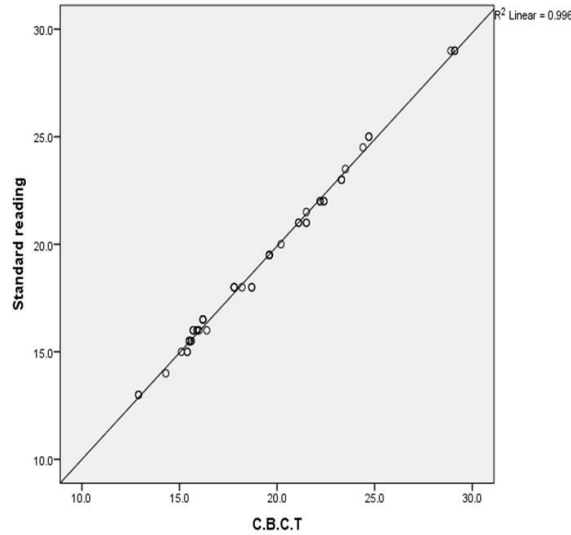


Figure 2. Scatter plot C.B.C.T. with standard reading

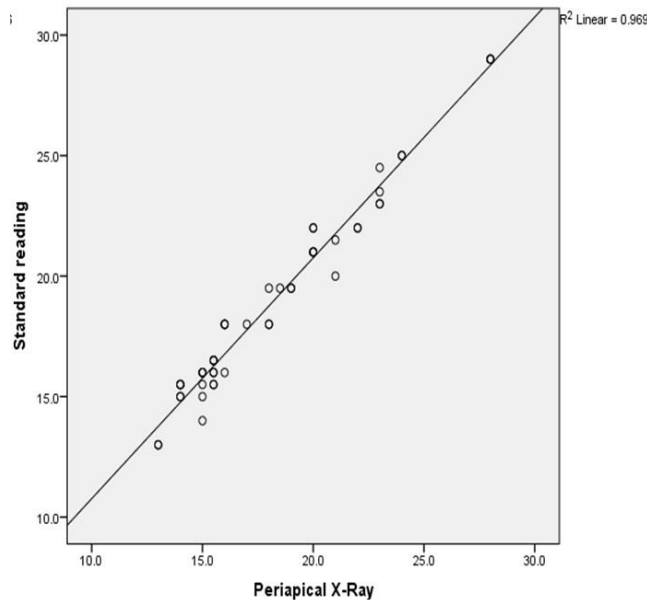


Figure 3. Scatter plot Periapical X-ray with standard reading

Figure (4) demonstrates a direct, strong, and significant correlation ($R^2=0.989$, $p\text{-value} < 0.0001$) between the Apex locator and Standard reading. Figure (5) depicts a similarly direct, strong, and significant correlation ($R^2=0.971$, $p\text{-value} < 0.0001$) between Periapical X-ray and C.B.C.T.

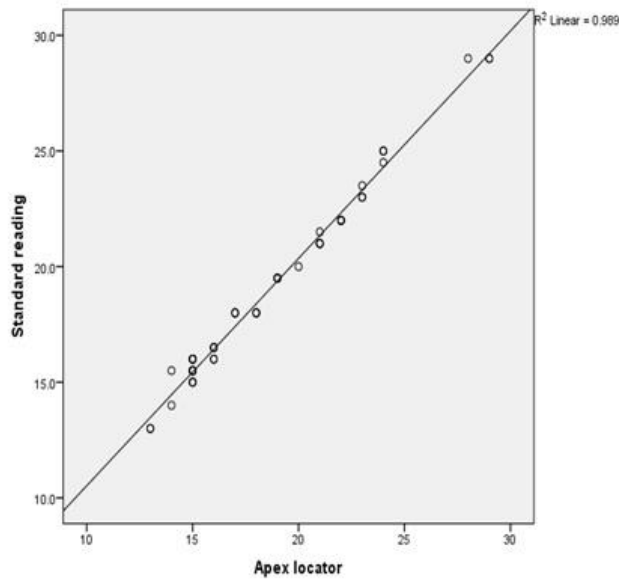


Figure 4. Scatter plot Apex locator with standard reading

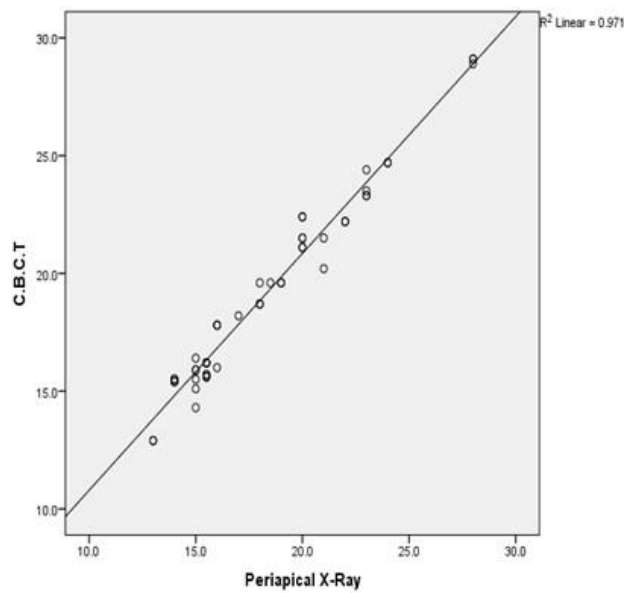


Figure 5. Scatter plot Periapical X-Ray with C.B.C.T

Furthermore, a direct, strong, and significant correlation is evident between the Apex locator and C.B.C.T. ($R^2=0.995$, p -value < 0.0001 , Figure (6)). In Figure (7), a direct, strong, and significant correlation is observed between the Apex locator and Periapical X-ray ($R^2=0.972$, p -value < 0.0001).

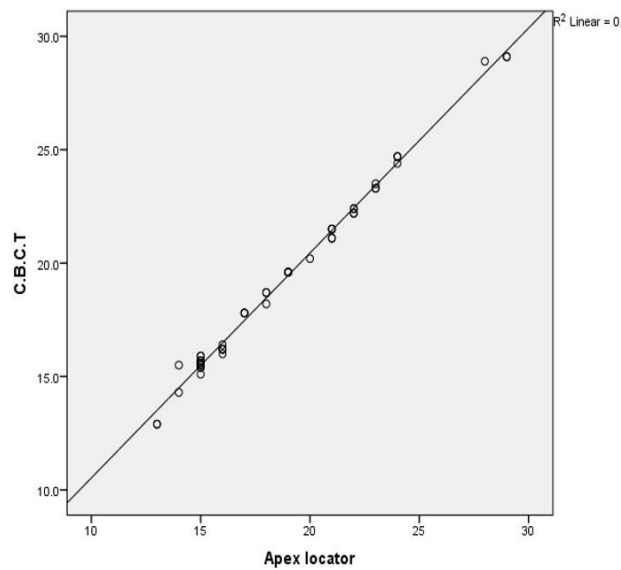


Figure 6. Scatter plot Apex locator with C.B.C.T

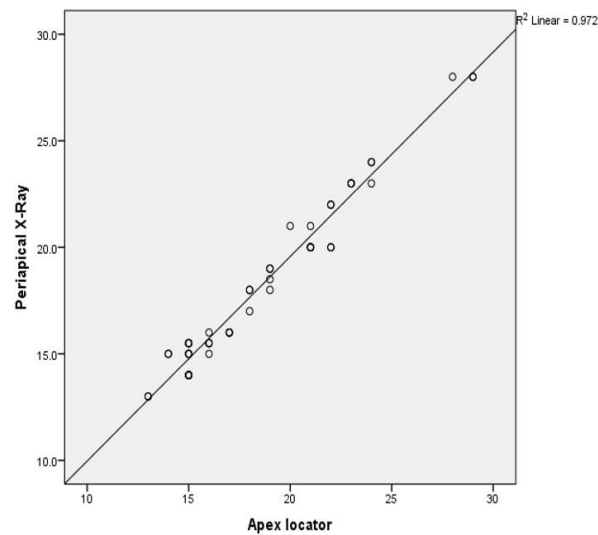


Figure 7. Scatter plot Apex locator with Periapical X-ray

Discussion

The position of the apical foramen can be ascertained using various methods, including periapical radiographies, which is the most widely used method (Bassam et al., 2021; Chaudhary et al., 2018; Nguyen & van Pham, 2020; Patel et al., 2015; Sherrard et al., 2010; Tsai et al., 2012; Yılmaz et al., 2017).

The study followed guidelines from the American Association of Endodontists and the American Academy of Oral and Maxillofacial Radiology for using CBCT in endodontic treatment. CBCT is recommended for diagnosing dental periapical issues when clinical signs are unclear or nonspecific, and for poorly localized symptoms related to untreated teeth. Many professionals prefer electronic apex locators (EALs) to regulate root canal W.L., despite the pros and cons of periapical radiography (Horner et al., 2015).

Ravanshad et al. conducted a comparison between EAL and radiography for W.L. determination in a study involving 84 patients. The results indicated that when it comes to the percentages of acceptable and short cases, the effectiveness of endodontic treatment using electronic apex locators is fair. Previous studies have emphasized the importance of WL measurement to avoid treatment failure and complications (Colceriu-Şimon et al., 2019; Kim et al., 2008; Van Pham, 2021; Vieyra et al., 2010). C.B.C.T. has been suggested as a reliable method for WL assessment (de Morais et al., 2016).

The W.L. refers to the measurement from the central reference point to the precise location where root canal preparation and obturation should conclude. Incomplete debridement, excessive filling, and underfilling can be caused by overextending or underextending the W.L., which can result in treatment failure or problems like postoperative discomfort and swelling, periapical infection, and even tooth loss (Bassam et al., 2021; Chaudhary et al., 2018). Working length measurement has commonly been accomplished using radiographic techniques such as periapical, digital, and C.B.C.T. Furthermore, due to their objectivity and lack of invasiveness, E.A.L.s have also become widely used in endodontics (Tsai et al., 2012; Yılmaz et al., 2017). However, each method has advantages and limitations; Based on this, this study was necessary to evaluate the precision of determining W.L. utilizing C.B.C.T, traditional periapical radiography, and electronic apex finders.

Cone-Beam Computed Tomography (CBCT) is a 3D imaging modality that provides accurate measurements of the W.L. of teeth (Patel et al., 2015). Morais et al. juxtaposed periapical radiography, C.B.C.T., and E.A.L., concluding that C.B.C.T. surpassed the other two techniques in terms of accuracy (de Morais et al., 2016). Tsai et al. compared the accuracy of C.B.C.T. and P.A. radiography and found that C.B.C.T. was excellent for lesions larger than 1.4 mm, while P.A. radiography was poor for all simulated lesion sizes (Tsai et al., 2012). Yildirim et al. likewise discovered that C.B.C.T. proved to be the most precise approach for assessing root canal W.L., achieving an accuracy rate of 70% (Yildirim et al., 2017) These studies confirm the

superiority of C.B.C.T. accuracy. Contrary to the above studies, the research by Pham et al. showed that the accuracies of E.A.L. devices were better than C.B.C.T. The difference in results may be caused by the device version, device error, and personnel error (Nguyen & van Pham, 2020).

The remarkable precision of C.B.C.T. can be ascribed to its capacity to offer three-dimensional visuals of the tooth and the neighboring structures, enabling enhanced observation of the root canal and its structural features. In contrast, periapical radiography provides only a two-dimensional image and may suffer from distortion and superimposition of structures. In addition, E.A.L.s depend on electrical resistance to pinpoint the position of the apical constriction, which can be influenced by variables like the moisture level within the root canal and the existence of metallic restorations (Patel et al., 2015). Cone-beam computed tomography (CBCT) provides more accurate W.L. measurements in complex root canal morphologies and curved canals, where P.A.R. and A.F. may not be accurate (Nguyen & van Pham, 2020; Van Pham, 2021). However, C.B.C.T. use in endodontic treatment is controversial due to increased radiation exposure (Colceriu-Şimon et al., 2019). To address concerns about radiation exposure, the US-based Guideline 3 statement advises using C.B.C.T. only when conventional dental radiography or alternative imaging methods are insufficient (Horner et al., 2015).

The present study found a strong positive correlation between the investigated methods. Janner et al. compared C.B.C.T. scans and standard clinical methods for measuring endodontic W.L. and found a strong correlation between C.B.C.T. images and E.A.L. readings (Janner et al., 2011). In a study of the accuracy and reliability of tooth-length and root-length readings using C.B.C.T. volumetric data, Sherrard et al. discovered that C.B.C.T. scans are at least as accurate and reliable as periapical radiography in assessing root (Sherrard et al., 2010). Kamaraj et al. compared five methods of determining work length and found that C.B.C.T. has a similar correlation with E.A.L. and actual length, indicating that it can be a reliable alternative for determining W.L (Kamaraj et al., 2020).

In summary, C.B.C.T. is more accurate than periapical radiography and E.A.L. in determining W.L., especially in teeth with complex canals. However, selecting the appropriate method should be based on individual case characteristics and each method's potential risks and benefits.

The study had limitations, such as the cost of C.B.C.T. and periapical radiography, which deterred some patients from participating; time constraints, lack of cooperation from some participants, and image distortion were also limitations.

Conclusion

The C.B.C.T. is a more accurate method for determining the W.L. than traditional radiography and apex finder, but its use should be limited to cases where traditional methods are insufficient or additional information is required. Additional investigation is required to assess the enduring consequences of radiation exposure stemming from C.B.C.T. and how it influences patient results.

Acknowledgements

We sincerely thank our research supervisor, participants, colleagues, and loved ones for contributing to this article.

References

- Bassam, S., El-Ahmar, R., Salloum, S., & Ayoub, S. (2021). Endodontic postoperative flare-up: An update. *Saudi Dental Journal*, 33(7), 386–394. <https://doi.org/10.1016/j.sdentj.2021.05.005>
- Chaudhary, S., Gharti, A., & Adhikari, B. (2018). An in vivo comparison of accuracy of two electronic apex locators in determining working length using stainless steel and nickel titanium files. *Clinical, Cosmetic and Investigational Dentistry*, 10, 75–82. <https://doi.org/10.2147/CCIDE.S158882>
- Colceriu-Şimon, I. M., Băciuţ, M., Ştiufiuc, R. I., Aghiorghiesei, A., Țărmure, V., Lenghel, M., ... Băciuţ, G. (2019). Clinical indications and radiation doses of cone beam computed tomography in orthodontics. *Medicine and Pharmacy Reports*, 92(4), 346–351. <https://doi.org/10.15386/mpr-1434>
- de Moraes, A. L. G., de Alencar, A. H. G., de Araújo Estrela, C. R., Decurcio, D. A., & Estrela, C. (2016). Working length determination using cone-beam computed tomography, periapical radiography and electronic apex locator in teeth with apical periodontitis: A clinical study. *Iranian Endodontic Journal*, 11(3), 164–168. <https://doi.org/10.7508/iej.2016.03.003>
- Horner, K., O'Malley, L., Taylor, K., & Glenny, A. M. (2015). Guidelines for clinical use of CBCT: A review. *Dentomaxillofacial Radiology*, 44(1), 20140225. <https://doi.org/10.1259/dmfr.20140225>
- Janner, S. F. M., Jeger, F. B., Lussi, A., & Bornstein, M. M. (2011). Precision of endodontic working length measurements: A pilot investigation comparing cone-beam computed tomography scanning with standard measurement techniques. *Journal of Endodontics*, 37(8), 1046–1051. <https://doi.org/10.1016/j.joen.2011.05.005>
- Kamaraj, P. S., Parandhaman, H., & Raguganesh, V. (2020). Comparison of Five different methods of Working length determination: An ex vivo study. *Endodontology*, 32(4), 187–192. https://doi.org/10.4103/endo.endo_30_20
- Kim, E., Marmo, M., Lee, C. Y., Oh, N. S., & Kim, I. K. (2008). An in vivo comparison of working length determination by only root-ZX apex locator versus combining root-ZX apex locator with radiographs using a new impression technique. *Oral Surgery, Oral Medicine, Oral Pathology, Oral Radiology and Endodontology*, 105(4), e79–e83. <https://doi.org/10.1016/j.tripleo.2007.12.009>
- Nguyen, P. N., & van Pham, K. (2020). Endodontic length measurements using different modalities: An in vitro study. *Journal of International Society of Preventive and Community Dentistry*, 10(6), 752–

758. https://doi.org/10.4103/jispcd.JISPCD_357_20

- Patel, S., Durack, C., Abella, F., Shemesh, H., Roig, M., & Lemberg, K. (2015). Cone beam computed tomography in endodontics—a review. *International Endodontic Journal*, 48(1), 3–15.
- Sharma Col, C. M. C., & Arora Maj Gen V., M. G. V. (2010). Determination of working length of root canal. *Medical Journal Armed Forces India*, 66(3), 231–234. [https://doi.org/10.1016/s0377-1237\(10\)80044-9](https://doi.org/10.1016/s0377-1237(10)80044-9)
- Sherrard, J. F., Rossouw, P. E., Benson, B. W., Carrillo, R., & Buschang, P. H. (2010). Accuracy and reliability of tooth and root lengths measured on cone-beam computed tomographs. *American Journal of Orthodontics and Dentofacial Orthopedics*, 137(4 SUPPL.), S100–S108. <https://doi.org/10.1016/j.ajodo.2009.03.040>
- Sherwood, I. A., Piasecki, L., Pavula, S., Pradeepa, M. R., Divyameena, B., Nivedha, V., ... Valliapan, C. T. (2021). Clinical Evaluation of Apex Locators and Cone-Beam Computed Tomographic for Working Length Determination in Pulp Canal Obliterated Traumatized Maxillary Incisors. *Journal of Orofacial Research*, 20–28.
- Tsai, P., Torabinejad, M., Rice, D., & Azevedo, B. (2012). Accuracy of cone-beam computed tomography and periapical radiography in detecting small periapical lesions. *Journal of Endodontics*, 38(7), 965–970. <https://doi.org/10.1016/j.joen.2012.03.001>
- Van Pham, K. (2021). Endodontic length measurements using 3D Endo, cone-beam computed tomography, and electronic apex locator. *BMC Oral Health*, 21(1), 1–7. <https://doi.org/10.1186/s12903-021-01625-w>
- Vieyra, J. P., Acosta, J., & Mondaca, J. M. (2010). Comparison of working length determination with radiographs and two electronic apex locators. *International Endodontic Journal*, 43(1), 16–20.
- Yildirim, C., Aktan, A. M., Karataslioglu, E., Aksoy, F., Isman, O., & Culha, E. (2017). Performance of the working length determination using cone beam computed tomography, radiography and electronic apex locator, in comparisons to actual length. *Iranian Journal of Radiology*, 14(1). <https://doi.org/10.5812/iranjradiol.31007>
- Yılmaz, F., Kamburoğlu, K., & Şenel, B. (2017). Endodontic Working Length Measurement Using Cone-beam Computed Tomographic Images Obtained at Different Voxel Sizes and Field of Views, Periapical Radiography, and Apex Locator: A Comparative Ex Vivo Study. *Journal of Endodontics*, 43(1), 152–156. <https://doi.org/10.1016/j.joen.2016.09.019>